

OBSERVATION OF BITOT'S SPOTS AND SCLERAL MELANOCYTOSIS IN PRESCHOOL CHILDREN OF HILLY AREA.

Giramkar S.V.,

Head, Department of Zoology, PDEA's Annasaheb Magar College Hadapsar, Pune-28, M/S, India.

Abstract: A survey was carried out with the aim of observation of Bitot's spot and scleral melanocytosis among preschool children of rural area. Clinical examination of 437 preschool children was carried, WHO guidelines were followed. The data was collected and analyzed to find the prevalence of Vitamin A Deficiency (VAD). The present survey revealed the prevalence of Bitot's spots (4.5%) and scleral melanocytosis (5.75%) among the preschool children. These health issues might be due improper diet, lack of awareness about health, hygiene and hereditary disease etc. We brought parents attention on these health issues and created awareness about importance of vitamin A among them.

Keywords: Preschool children, Vitamin A deficiency, Bitot's spots, Scleral melanocytosis.

I. INTRODUCTION:

Most of the world's preschool children are suffering from vitamin A deficiency, it is highest prevalent in regions of South-East Asia and Africa (WHO, 2009). Deficiency of vitamin A is still a major nutritional issue among the lower income countries. The VAD causes xerophthalmia, night blindness and Bitot's spots to severe corneal xerosis or sometimes complete blindness (Zekariyas Sahile et.al. 2020). This dietary nutrient should be in adequate amount for normal vision and immunity. Vitamin A also boosts cellular growth, immunity and development (Amare Tariku et.al. 2016). VAD is prevalent in Africa where preschool suffering from night blindness but it is four times more prevalent in South East Asia (Zekariyas Sahile et.al. 2020). Scleral melanocytosis is hereditary hyperpigmentation commonly found in the sclera of Asian population. Scleral melanocytosis generally appear as two-sided spots of black to grey pigmentation in sclerae. Histological examination of these spots shows dendritic melanocytes, it may be related benign condition which is commonly appear in Asian ancestries (Leung AKC. 1999). The scleral melanocytosis may be nevus of Ota which is a melanosis that involves the appearance of patchy gray, blue or black discoloration of sclera to hyperpigmentation of entire area between the outer and inner layer of cornea and sclera, retina and optic nerve (Bang P. 2015). Hence, there was an urgent need to carry out a survey of children in rural areas in Maharashtra regarding the same.

II. MATERIAL AND METHODS:

A survey was carried out in and around a 15 km hilly region (18°10'0"N 73°51'0"E) of Bhor Tehsil, M/S, India. The aim of survey was to check health related issues in preschool children of hilly area. In this survey, 437 preschool children of age group 4 to 7 years were examined. Especially eyes were examined to observe Bitot's spots and scleral melanocytosis. Sub-clinical examinations were carried out by trained surveyors (Plate-1). Photographs were taken by using Sony cyber-shot DSCW230 12 MP Digital Camera with 4x Optical Zoom. Guidelines provided by WHO were followed during the survey. Data was collected and analysed by using Microsoft Excel 2010.

III. RESULT AND DISCUSSION:

In this study, 437 preschool children of age group 4 to 7 years were examined. Clinical examination for Bitot's spots and scleral melanocytosis was carried out (Plate-1).



Plate-1: Clinical examination of preschool children.

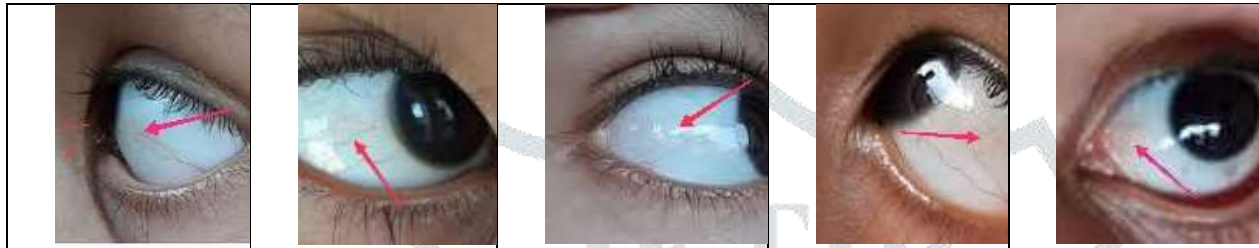


Plate-2: Observation of Bitot's spots in white portion of eyes.

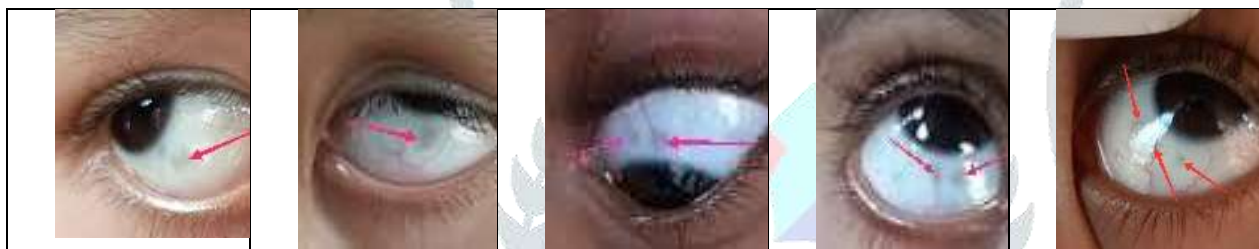

Plate-3: Observation of scleral melanocytosis in white portion of eyes.

Bitot's spots were observed in 4.5% of preschool children. It was noted that in the conjunctiva of eyes Bitot's spots were located to temporal portion of cornea (Plate-2). These Bitot's spots were typically triangular keratinized spots. The lesions of Bitot's spots were dry patches not wetted by tears. Few Bitot's spots were appeared foamy. Bitot's spots are localized areas of xerosis its appearance might be depends accumulation of bacteria on a site of bulbar portion of conjunctiva of eyes (William J. Darby et. al. 1960). Presence of Bitot's spots indicates vitamin A deficiency in population (D.W. Khandait et.al.1999; NMB 2003).

Vitamin A deficiency is major issue in developing countries due to malnourishment especially caused by decreased intake of pro-vitamin carotenoids. Generally young children are at high risk due to higher nutritional demands (Sharma A at al. 2014). Deficiency of vitamin A causes Bitot's spots through metaplasia of the conjunctival epithelium and it causes deposition of keratin in the stratum corneum of the conjunctiva (Umesh Krishna et. al. 2016). The foamy appearance observed in Bitot's spots in present study might be due to gas produced by gram-positive bacilli (Sommer A et al. 1981).

In present study, 5.75% of scleral melanocytosis were observed in preschool children. These were blackish grey spots observed in scleral area of the eyes (Plate-3). The children with sclera melanocytosis were with normal vision. Scleral melanocytosis is a common gray-blue pigmentation in the scleral tissues of the eyes of children (Giramkar S. V. 2020). Histological examination of these spots shows dendritic melanocytes, it may be related benign condition which is commonly appear in Asian ancestries (Leung AKC. 1999). The scleral melanocytosis may be nevus of Ota which is a melanosis that involves the appearance of patchy gray, blue or black discoloration of sclera to hyperpigmentation of entire area between the outer and inner layer of cornea and sclera, retina and optic nerve (Bang P. 2015).

These health issues might be due improper diet, lack of awareness about health and hygiene etc. We brought parents attention on these health issues and created awareness about importance of vitamin A among them.

IV. CONCLUSION:

The present study revealed the prevalence of Bitot's spots and scleral melanocytosis among the preschool children. These health issues might be due improper diet, lack of awareness about health, hygiene and hereditary disease etc.

We brought parents attention on these health issues and created awareness about importance of vitamin A among them. There is need of histological examination and further study of scleral melanocytosis.

V. ACKNOWLEDGEMENTS:

The author wishes to thank Dr. Ramchandra P. Babar M.D. Ph.D. (AY. PAED) Pediatrician and Neonatologist, Kashyap Child Clinic, Kharadi, Pune for critical suggestions during necessary discussions. Thanks to Principal Dr. Pandit Shelke, Annasaheb Magar College Hadapsar, Pune for valuable support and thanks to Mr. Nikhil Giramkar for data analysis. Thanks to all students who have offered every possible help during survey.

VI. REFERENCES:

Amare Tariku et.al. Vitamin-A deficiency and its determinants among preschool children: A community based cross-sectional study in Ethiopia. BMC Res Notes. 2016;9: 323. DOI: 10.1186/s13104-016-2134-z, pp1-8.

Bang P. Scleral melanocytosis. *Consultant for Pediatricians*. 2015;14 (12): 572.

D.W. Khandait et.al. Vitamin A intake and xerophthalmia among Indian children. *Public Health* 1999; 113 (2): 69-72.

Giramkar S. V. Prevalence of vitamin a deficiency, scleral melanocytosis, tooth decay and skin infection among rural preschool children in mulshi tehsil, m/s, india. *Asian Journal of Advances in Research*. 2020; 4(3): 1-5.

Leung AKC. A spot in the eye. *Am Fam Physican*. 1999; 59(1): 163-164.

NMB; National Nutrition Monitoring Bureau (NNMB). Prevalence of Micronutrient deficiencies. Hyderabad, India: National Institute of Nutrition; 2003.

Sharma A at al. *Int J Prev Med*. 2014; 5(8):1058-1059.

Sommer A et al. *Arch Ophthalmol*. 1981; 99(11): 2014-2027.

Umesh Krishna et. al. Management of Bitot's Spot. *Cornea-Ophthalmic Pearls*. 2016; 35-36.

WHO. World Health Organization (WHO). Global prevalence of vitamin A deficiency in populations at risk 1995-2005. WHO Global Database on vitamin A deficiency. Geneva: WHO; 2009.

William J. Darby et. al. Bitot's Spots and Vitamin A Deficiency. *NUTRITION-Public Health Reports*. 1960; Vol. 75, Now 8: 738-743.

Zekariyas Sahile et.al. Prevalence of Vitamin A Deficiency among Preschool Children in Ethiopia: A systematic review and metaanalysis. *BioMed Research International*. 2020. [Article ID 8032894:1-12].